

Septodont Case Studies *Collection*

No. 09 - October 2014

R.T.R.

β -TCP FOR BONE REGENERATION

GIUSEPPE GALVAGNA
PAOLO BRUNAMONTI BINELLO
MASSIMO GALLI
MAURO LABANCA

R.T.R.

ALLOPLASTIC GRAFTS - β -TCP

MARIO ERNESTO GARCÍA-BRISÉÑO

BIODENTINE™

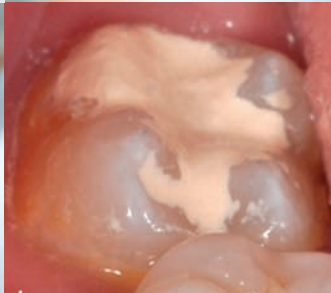
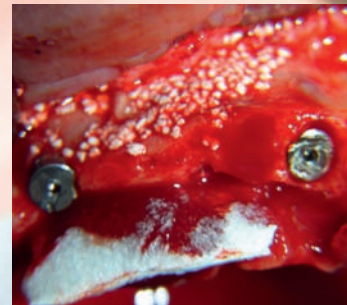PULPOTOMY ON PRIMARY MOLARS

LUC MARTENS & RITA CAUWELS

BIODENTINE™

PULP CAPPING

LUC MARTENS & RITA CAUWELS



Editorial



© Jeremy Allen | Dreamstime.com

Since its foundation Septodont has developed, manufactured and distributed a wide range of high quality products for dental professionals.

Septodont recently innovated in the field of gingival preparation, composites and dentine care with the introduction of Racegel, the N'Durance® line and Biodentine™, which are appreciated by clinicians around the globe.

Septodont created the “Septodont Case Studies Collection” to share their experience and the benefits of using these innovations in your daily practice.

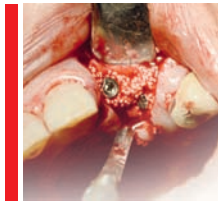This Collection consists in a series of case reports and is published on a regular basis.

This 9th issue is dedicated to two of Septodont's innovative products:

- R.T.R., an easy-to-use synthetic bone grafting material. In addition to its ability to provide an optimal osteoconductive environment to promote the growth of new dense bone, R.T.R. comes in 3 different presentations to suit all the clinical situations.
- Biodentine™, the first biocompatible and bioactive dentin replacement material. Biodentine™ uniqueness not only lies in its innovative bioactive and “pulp-protective” chemistry, but also in its universal application, both in the crown and in the root.



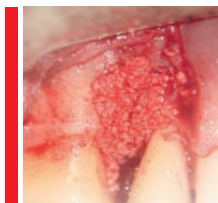
Content



Use of β -tricalcium phosphate for bone regeneration in oral surgery

04

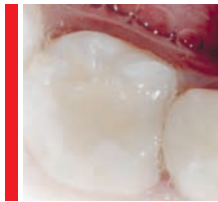Giuseppe Galvagna, Paolo Brunamonti Binello,
Massimo Galli and Mauro Labanca



Alloplastic Grafts - Beta-tricalcium phosphate

14

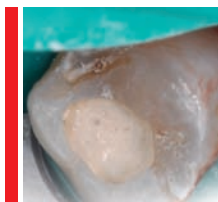Mario Ernesto García-Briseño



Biodentine™ - Pulpotomy on primary molars

21

Luc Martens and Rita Cauwels

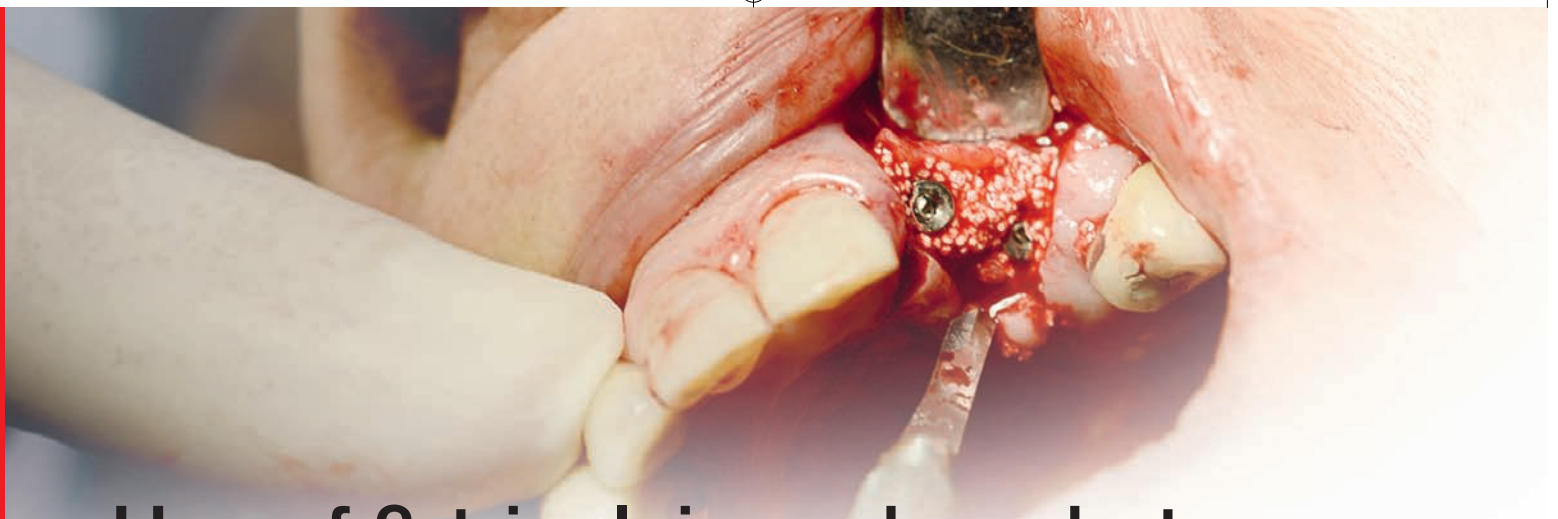

Biodentine™ - Pulp capping

26

Luc Martens and Rita Cauwels





Use of β -tricalcium phosphate for bone regeneration in oral surgery

A multicenter study to evaluate the clinical applications of R.T.R. (Resorbable Tissue Replacement)

Giuseppe Galvagna: Private practice, Catania, Italy

Paolo Brunamonti Binello: Consultant Professor, University of Genoa

Massimo Galli: Private practice, Pistoia, Italy

Mauro Labanca: Consultant Professor in Oral Surgery and Anatomy, Milan, Italy

In prosthetic implant rehabilitation, loss of bone volume in atrophic maxillae is one of the major problems faced by surgeons in their clinical practice. In the presence of horizontal and vertical bone defects, atrophic ridges need to be restored to make them suitable for implant placement and for restoration of masticatory and aesthetical functions.

For this reason, in recent years the term “GBR” has been closely associated with the concept of prosthetically guided implantology.

The purpose of this study is to demonstrate the osteoconductive properties of synthetic biomaterials, particularly β -tricalcium phosphate or R.T.R., and its benefit for a suitable GBR.

Introduction

In order to obtain effective bone regeneration using natural or synthetic fillers, a series of favourable conditions must occur that allow the body to perform the bone growth (15) as follows:

- presence of a blood clot with a high concentration of mesenchymal stem cells (MSC) capable of evolving in the osteoblast line and of endothelial cells forming a rich vascular network
- presence of vital bone tissue, from which osteogenic and angiogenic cells originate

through adequately prepared surrounding bone (cortical perforation)

- stabilization and maintenance of volume underneath the membrane
- protection of blood clot with a membrane, with the function of the stabilization of the clot, protecting growing vascular structures and blocking the migration of epithelial cells, which proliferate faster than bone cells.

In 1980 Nyman and Karring first introduced the concept of guided tissue regeneration (GTR) of

periodontal tissues, showing that the cells of soft tissue can grow faster than bone tissue (10). Thus, based on the results obtained, the migration of soft tissue cells above the implanted material must be stopped, thereby blocking migration within the porosity of the same material, thus promoting osseointegration rather than fibrointegration. The main characteristic of a membrane should be semi-permeability, i.e. the presence of porosity approximately 22 microns in diameter. Initially, a thin vascular network and a primary fibrous osteoid tissue -also called primary spongiosa- will begin to form within the clot. The latter is later mineralized thanks to osteoblasts that cover its surface, forming a new poorly calcified cortical bone.

The process stops when intertrabecular spaces narrow due to the formation of new bone tissue, until they reach the characteristic dimensions of Havers channel which, along with concentric lamellae, originate primary osteomas. All this occurs during the first 3-4 months, though actual bone remodelling requires more time, as it creates secondary spongiosa.

Research conducted by Hämmerle in 1996 (11) on human subjects confirmed what had previously been observed in animals, i.e. in the presence of large bone defects, regeneration can be limited to the more peripheral areas of the defect, while less activity is observed in the central area, where granules of biomaterial remain over time, though less frequently when tricalcium phosphate is used. The process of ossification always starts from the walls of the defect toward the center of the clot, along the newly formed vessels.

A number of studies clearly describe the regenerative ability of autologous bone compared with synthetic biomaterials, but unfortunately not without negative aspects. Indeed, collection from the donor site is very often painful for the patient; additionally, this results in longer surgical procedures and postoperative pain ; finally, the implanted material has a high degree of resorption (not a negligible factor).

The materials used for bone regeneration are grouped into: Autogenous bone, allogenic bone, xenogenic bone, alloplastic bone.

Graft biomaterials

The alloplastic biomaterials available on the market represent an excellent alternative to autologous bone graft and are classified into two large groups: bioinert and bioactive, according to their interaction when they come into contact with the receiving site.

The main requirement of a synthetic biomaterial is to have a surface porosity that must promote colonization and development within its structure. These porosities must measure between 200/400 microns in diameter (Lynch et al., 2000; Bauer and Muschler, 2000). Synthetic biomaterials have been the subject of many studies, though their long term results have not always been considered. (1-2-3)

Today, osteoblastic cells or bone morphogenetic proteins (BMP obtained with in vitro cultures) can be added to a graft material (4-5) to enhance its osteoinductive and osteoconductive abilities and therefore reduce the time required for cells colonization. (6-7-8)

Among alloplastic biomaterials, β -tricalcium phosphate is the one that mostly displays a stable bond with bone neoformation; indeed, its characteristics have made it suitable for use in orthopedics since the early 1900s. In the presence of H₂O it becomes instable, turning into hydroxyapatite, and this characteristic makes it suitable as an osteoconductive material (Coetree, 1980, De Leonardis and Pecora, 1999; 2000).

β -TCP is characterized by a lower Ca/P ratio, which makes it more soluble than natural apatite. The Beta form is commonly obtained by mixing calcitis (CC) and dibasic calcium phosphate anhydrous (DCPA). The product obtained is rapidly cooled, and Alfa-TCP is obtained. Conversely, extended repeat baking at 800/950°C results in the beta form (9-12-13).

Multiple studies conducted on the TC and bone interaction have shown that histological examination at four months shows an initial bone neoformation in the intergranular spaces and in the surface porosity that helps guided bone formation. Indeed, the granules are reabsorbed by phagocytosis, releasing Ca/Mg and phos-

phates in the surrounding bone tissue, thereby activating alkaline phosphatase, a key ossification process. Between 6 and 18 months, fibroblasts begin invading the biomaterial, activating the extracellular dissolution process which ends with the calcification phase. If this should occur sooner, graft integration, rather than biodegradation, would happen. (5-6-7-8).

R.T.R.

Synthetic, biocompatible and totally resorbable 99% pure tricalcium phosphate bone replacement, available in granules and in a cone shape, for regeneration in periodontal defects, implant, post-extraction bone defects and bone lesions following endodontic surgery.

The micro and macro-porous R.T.R. structure, with macropores measuring between 100 and 400 μm and micropores measuring less than 10 μm .

These morphological characteristics allow excellent osteogenic cell in-depth colonization and easy compacting.

Unlike hydroxyapatite, R.T.R. is progressively and totally reabsorbed, thereby releasing calcium and phosphate ions that participate actively in the formation of new bone tissue. Over a period of time between 6 and 9 months, which may vary according to the patient's physiological response, while stimulating bone regeneration, R.T.R. is progressively reabsorbed, leaving space for bone neoformation.

Indications:

- Post-extraction sites
- Filling post-extraction sites to maintain the dimensions of alveolar bone
- Implant defects
- Sinus lift procedure
- Reconstruction of peri-implant defects
- Filling periodontal pockets with two or more walls
- Residual cavities after oral surgery (like cyst)
- Filling defects after apicectomy
- Alveolar filling following extraction of impacted teeth.

Materials and methods

We conducted a multicenter study to evaluate the clinical application of R.T.R. (β -tricalcium phosphate).

This study examines the regeneration of bone defects with R.T.R. (β -tricalcium phosphate) in patients eligible for prosthetic implant rehabilitation. Patients were randomly selected, according to the following key criteria:

- aged between 20 and 60 years
- either male or female
- non-smokers
- in good general health
- having at least one crestal bone defect (no morphology and etiopathogenesis restrictions).

The cases treated were identified in the following clinical situations:

- Post-extraction sites
- Bone regeneration around implants placed in areas with bone loss or post-extraction.
- GBR (sinus lift or major bone defects).

In all cases, patients received antibiotic therapy with 1 gr every 8 h of Amoxicilline plus Clavulanic Acid (starting 24 hours before surgery up to day 5 post-surgery), repeated daily rinses with chlorhexidine and therapy with FANS (ibuprofen 800 mg/day in single dose), as necessary.

Case Report no.1

Patient: Female

Age: 30

History: odontogenic cyst in maxillary bone at 2.1.

Cyst was removed in October 2013. Vertical guided regeneration with resorbable membrane and R.T.R. was performed. Implant placement: bone peak follow-up intraoral X-ray in consecutive months. 2nd surgery ISQ value: 61.

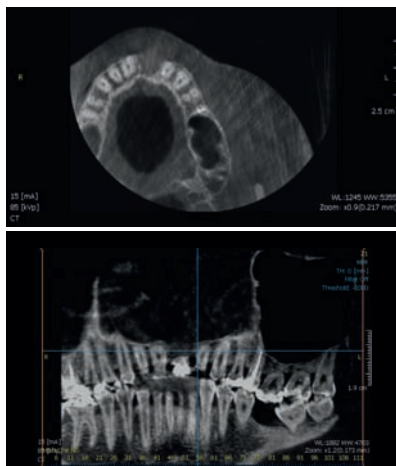


Fig. 1-4: Different projections of radiographic C.T images show the large bone defect in site 2.1.

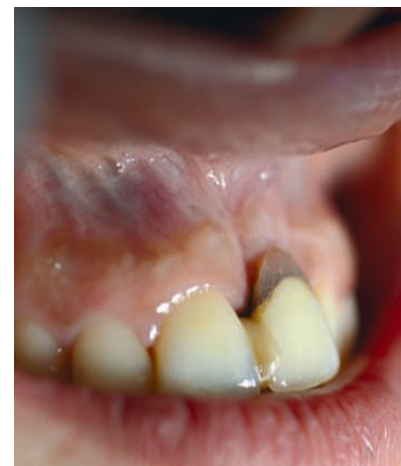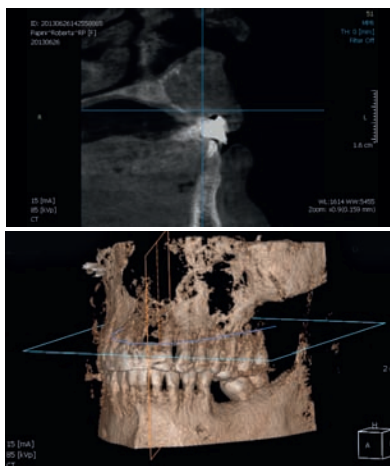


Fig. 5: Temporary prosthesis to cover the cosmetic defect.

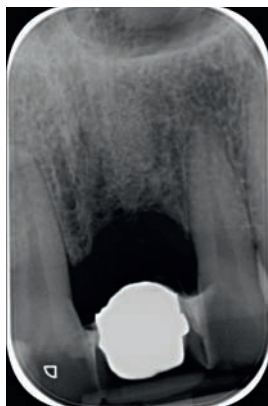


Fig. 6: X-ray image before grafting.

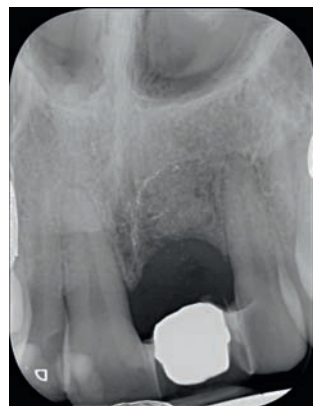

Fig. 7: X-ray image after 5 months.

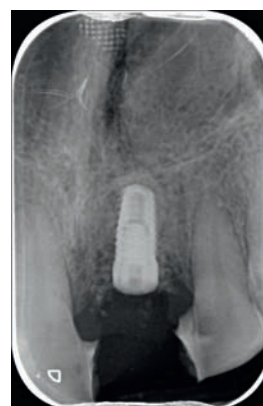

Fig. 8: X-ray after insertion of the implant.

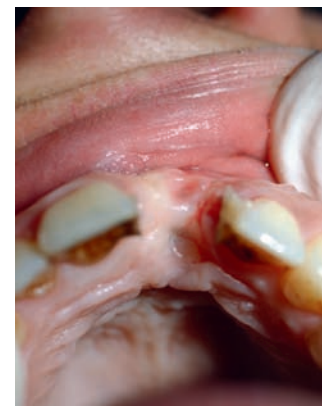

Fig. 9: The local objective examination and routine radiographic examination showed a good short-term healing.

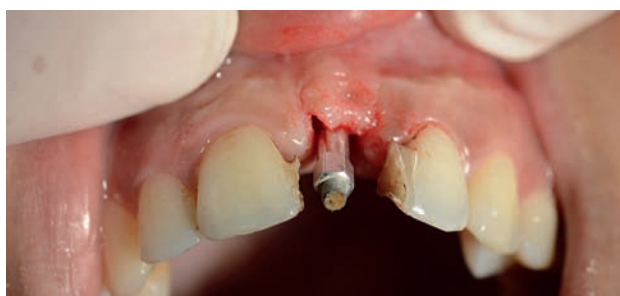

Fig. 10: The ISQ test confirms a good stability of the implant.

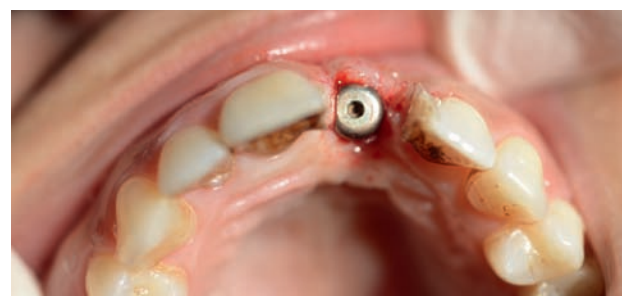

Fig. 11: To obtain a good aesthetics of the final prosthesis is important to condition the soft tissue with the healing screws that favors the emergence profile.

Case Report no.2

Patient: female

Age: 60

History: large cyst in upper maxillary bone extending from 2.2 to 1.1.

The cyst was removed and the cavity was filled with R.T.R. enhanced with PRGF (platelet-enriched plasma) and simultaneous placement of five implants was also performed.

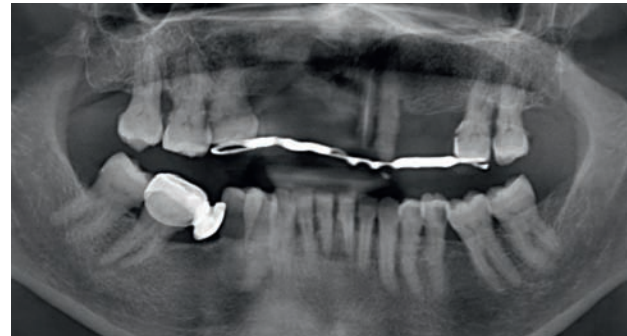
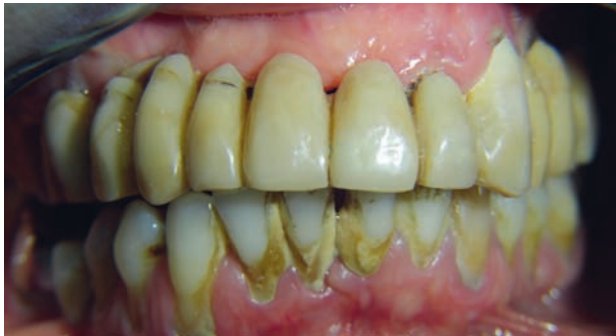
Fig. 12-13: Presence of large cysts of 2.1. The oral cavity examination shows a poor oral hygiene.

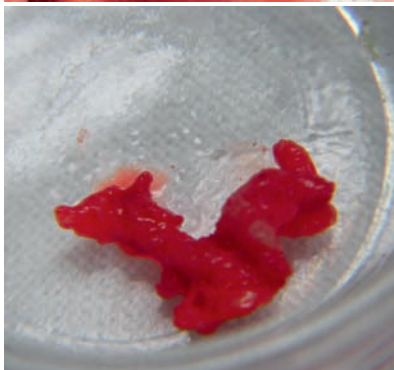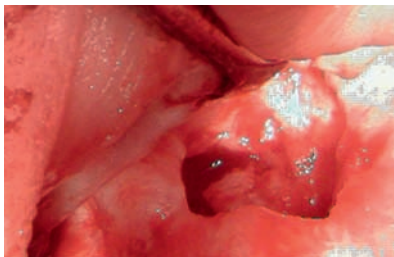


Fig. 14-15: Removal of the cyst; it is very important to remove all residual epithelial.

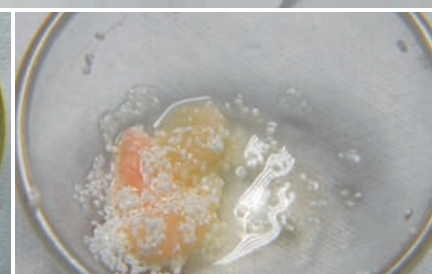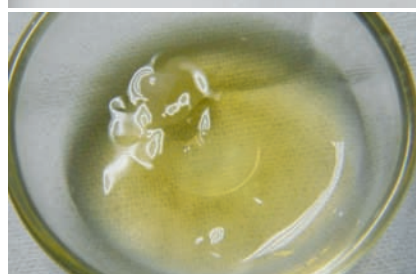

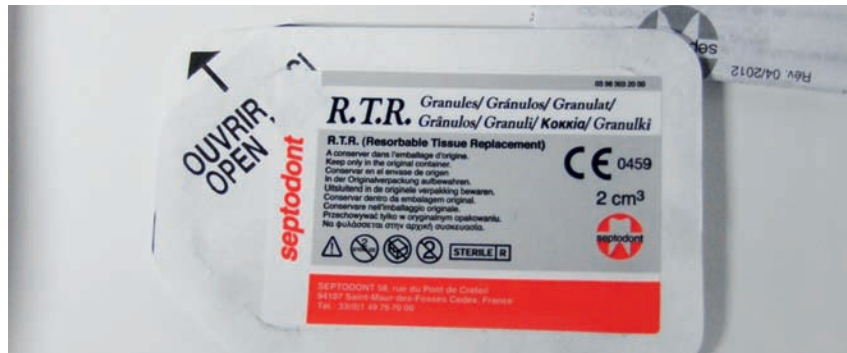
Fig. 16-17-18: Filling the bone cavity with granular R.T.R.

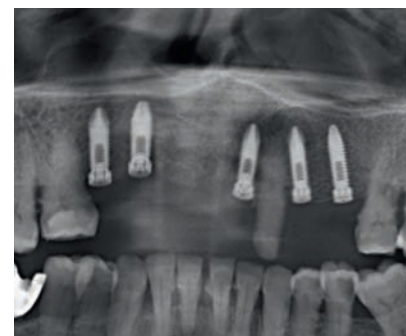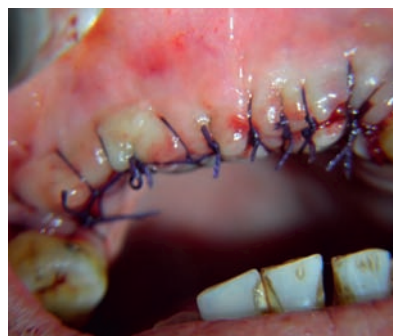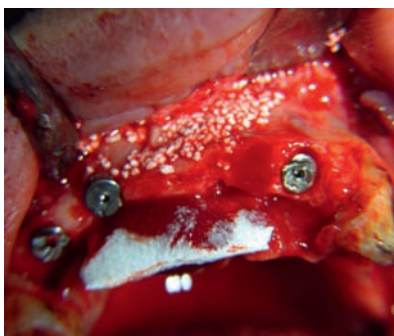


Fig. 19-20: During the same surgery were included five implants.

Fig. 21: X-ray control after five months.



Case Report no.3

Patient: female

Age: 50

History: severe atrophy of the alveolar ridge, upper right jaw, affecting the area of 1.3, 1.4, 1.5, 1.6. These teeth were extracted and the alveolar ridge was reconstructed with R.T.R., covering biomaterial with Tabotamp (oxidized cellulose).

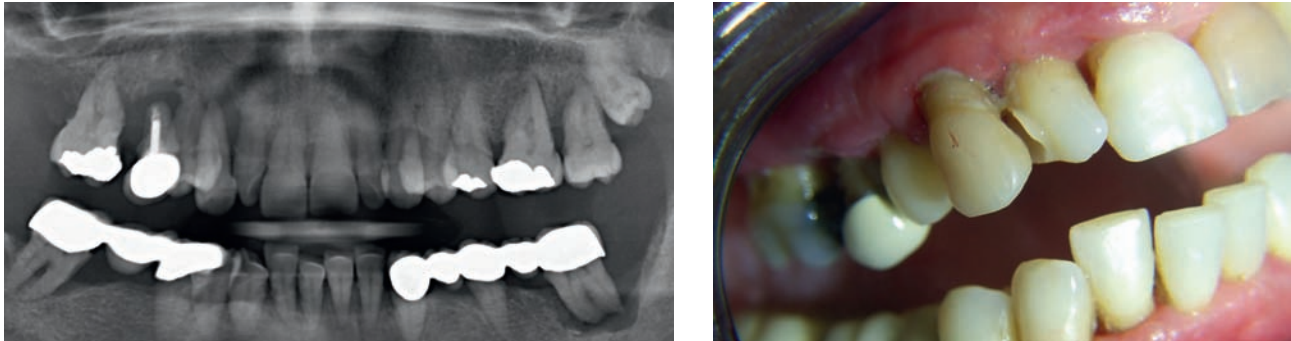


Fig. 22-23: Resorption of the alveolar process caused by periodontal disease. The local examination shows the class III mobility of the teeth.

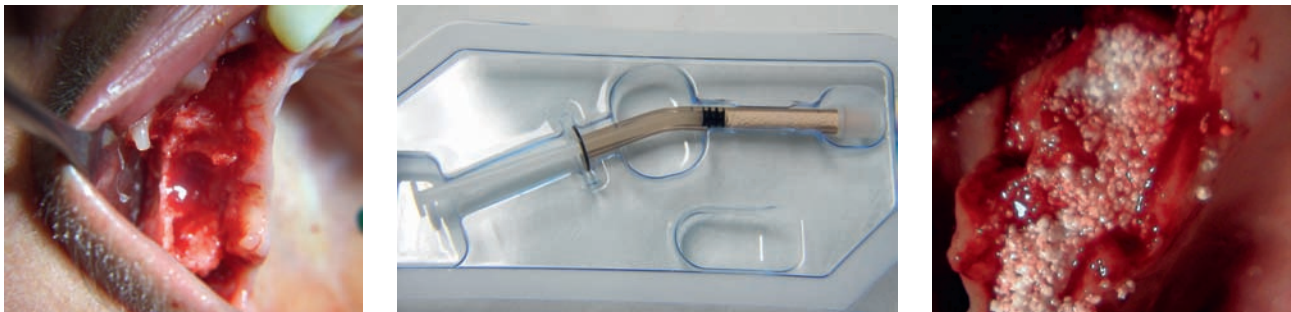

Fig. 24-25-26: Resorption of the alveolar process caused by periodontal disease. The local examination shows the class III mobility of the teeth.

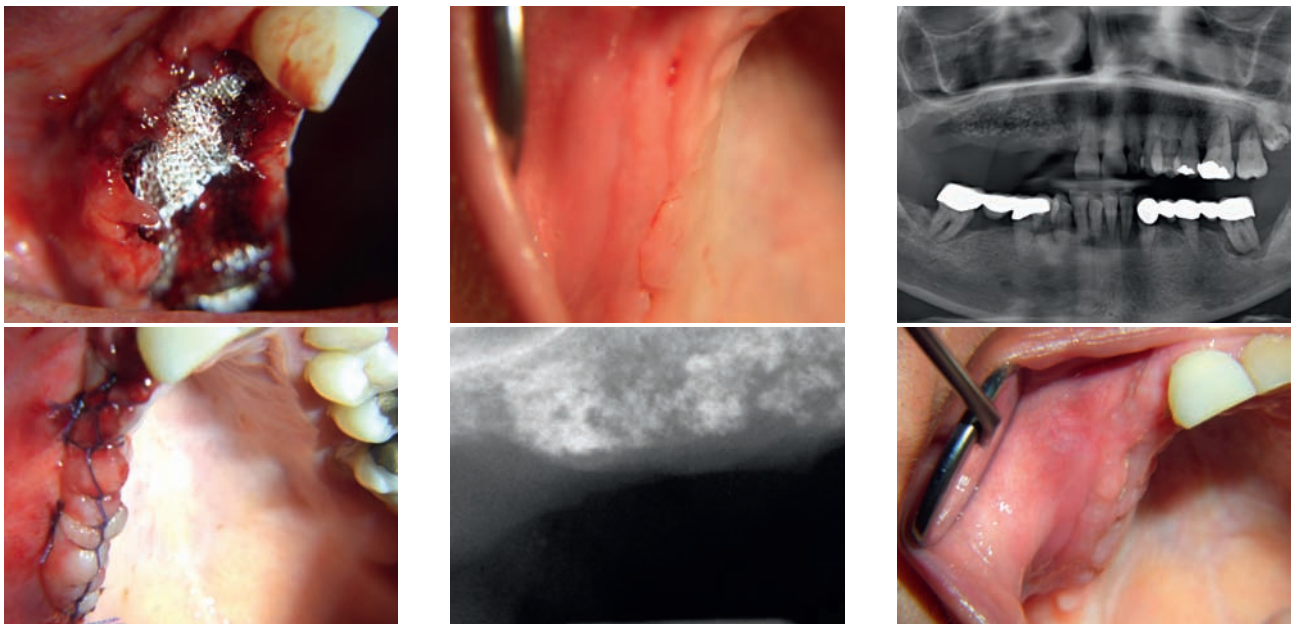


Fig. 27-28: Use of Tabotamp to cover the graft.

Fig. 29-30: The local examination after 10 days.

Fig. 31-32: The radiographic image after 4 months showed an increase in the vertical dimensions.



Case Report no.4

Patient: female

Age: 30

History: root fracture of 1.6, previously treated with root canal treatment and large crown composite reconstruction. The roots were carefully extracted, and an implant was placed, using the interdicular septum bone and by performing an elevation of the maxillary sinus with osteotomes. The alveoli were filled with R.T.R. and covered with a collagen membrane.

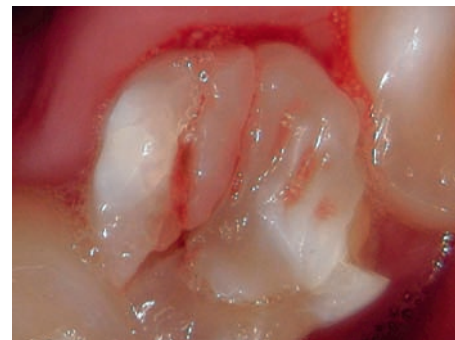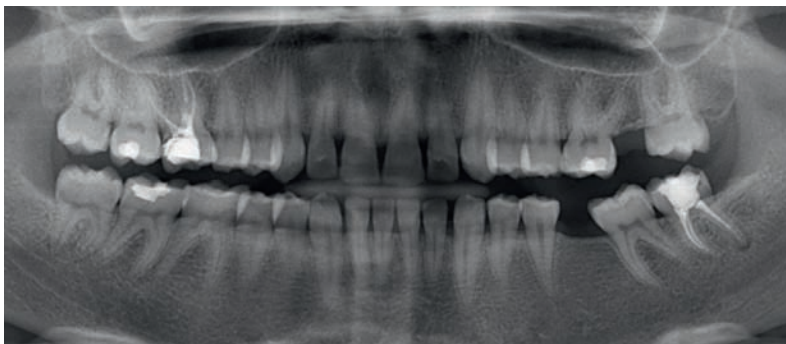


Fig. 33-34: Fracture of the first molar with the insertion of implant with post-extraction procedure.

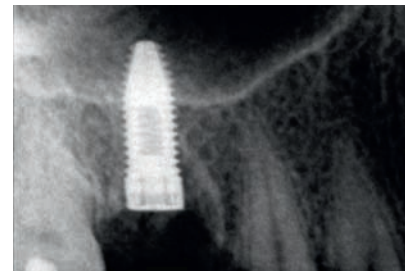
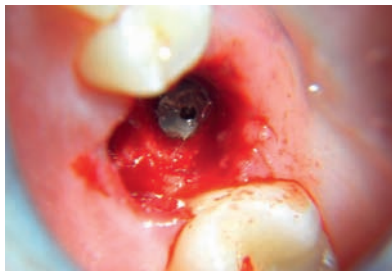
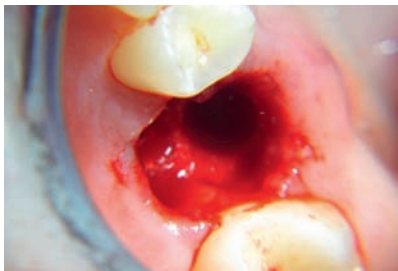
Fig. 35-36-37: Extraction was performed with piezosurgery technique to preserve the alveolar bone.

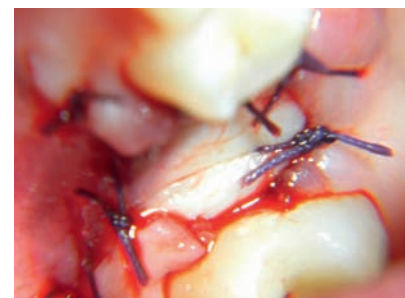
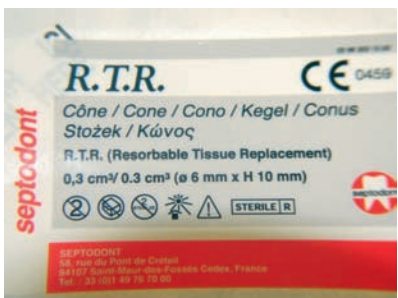
Fig. 38-39-40: The gap was filled using R.T.R.-size cone.

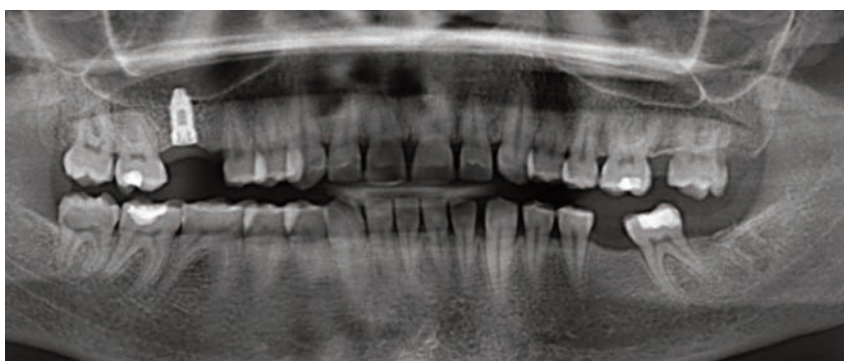
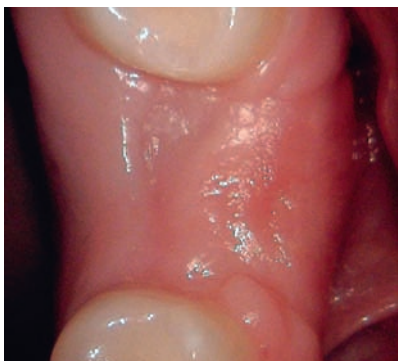

Fig. 41-42: The intraoral examination and radiographic examination after 4 months showed good integration of the implant.

Case Report no.5

Patient: female

Age: 64

History: loss of 2.2 and 2.3 due to trauma.

CT revealed a significant resorption of buccal vestibular alveolar process.

Two implants were placed (measuring 3.3 mm in diameter and 13 mm long) and the gap was filled with R.T.R.

Re-opening was done after 5 months and evaluation of osteointegration with Osstel.

2.2 showed a value of 22-ISQ, and 2.3 –ISQ 64.

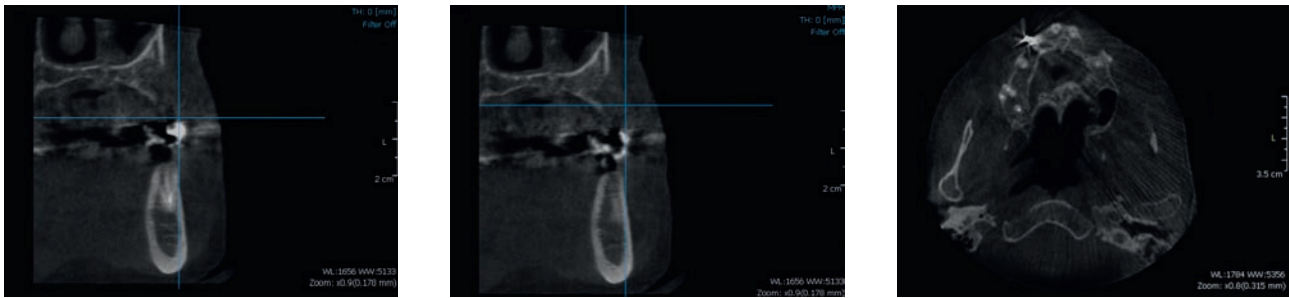

Fig. 43-44-45: Severe post-traumatic atrophy of the alveolar process in place 2.2- 2.3.

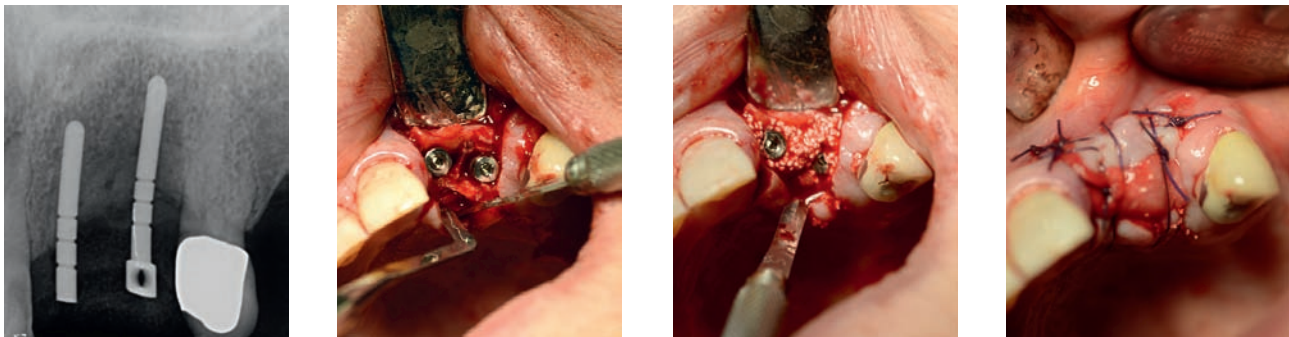


Fig. 46-47: Insertion of two implants with “split-crest” surgical technique.

Fig. 48-49: The gap between the two margin bone was filled with phosphate-tricalcium R.T.R.

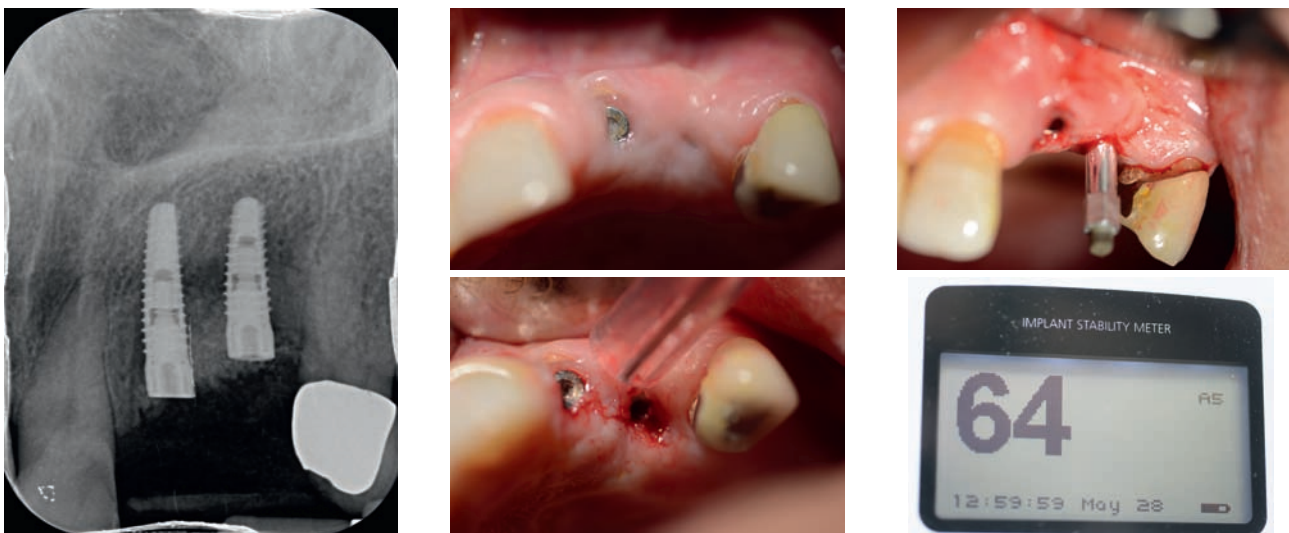


Fig. 50: X-ray control after 4 months showed a good bone density.

Fig. 51-52: The intraoral examination does appreciate a good recovery and an increase in bone volume.

Fig. 53-54: The ISQ value confirms a good osseointegration.

Case Report no.6

Patient: female

Age: 55

History: residual cyst at 3.6. To proceed to prosthetic molar rehabilitation with an implant, the cyst was extracted and the cavity was filled with R.T.R.; after a 4-month period for bone regeneration, the implant was placed.

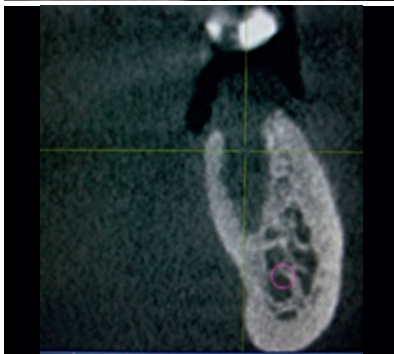
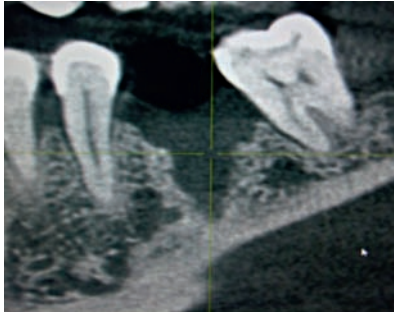


Fig. 55-56: The C.T. examination before surgery showed a residual cyst.

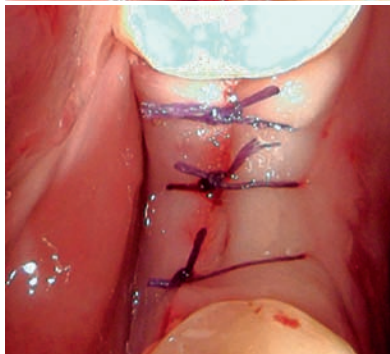
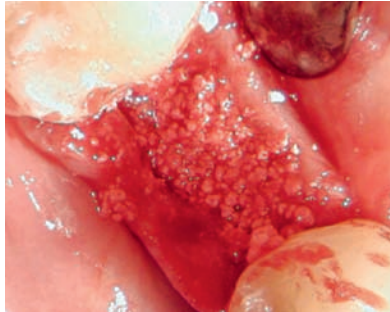


Fig. 57-58: After having removed the cyst, to speed up the healing time, the cavity has been filled with R.T.R. granules.

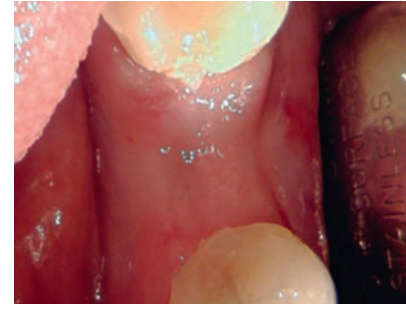

Fig. 59: Wound at 30 days.

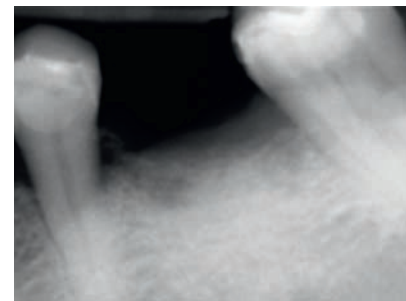



Fig. 60: X-ray at 3 months.

Conclusion

Based on the results obtained in the short term, the authors confirm the excellent properties of R.T.R., both in the first weeks of healing and in the following months, and they consider it an excellent alternative to autologous bone grafts. No inflammatory reactions or loss of bone volume evaluated clinically and radiographically

occurred in any of the cases examined. The most encouraging data came from the observation of the compactness and density of the bone neo-formation, which easily allowed the placement of implants with high ISQ values both during and after the placement of R.T.R. graft.



Authors (left to right)

Giuseppe Galvagna: Dental practitioner, Catania, Italy

Paolo Brunamonti Binello: Consultant Professor, University of Genoa. Galliera Hospital, Genoa, Italy

Massimo Galli: Oral surgeon, dental practitioner, Pistoia, Italy

Mauro Labanca: Professor of Oral Surgery and Anatomy, Milan, Italy

References

01. Labanca M., Leonida A., Rodella FL: Natural synthetic biomaterial in Dentistry: Science and ethics as criteria for their use. *Implantologia* 2008; 1:9-23
02. Ohgushi H, Caplan AI: Stem Cell Technology and Bioceramics: From Cell to Gene Engineering. *J Biomed Mater Res* 48(6): 913-927, 1999
03. Anselme K: Osteoblast adhesion on biomaterials. *Biomaterials* 2000 Apr; 21(7):667-81.
04. Toquet J, Roahanizadeh R, Guicheux J, Couillaud S, Passuti N, Daculsi G, Heymann D: Osteogenic Potential in vitro of human bone marrow cells cultured on macroporous biphasic
05. Maddox E, Zhan M, Mundy GR, Drohan WN, Burgess WH: Optimizing human demineralized bone matrix for clinical application. *Tissue Eng* 6(4): 441-448, 2000 calcium phosphate ceramic. *J Biomed Mater Res.* 1999 Jan; 44(1):98-108.
06. Gauthier O, Bouler JM, Aguado E, Pilet P, Daculsi G: Macroporous biphasic calcium phosphate ceramics: influence of macropore diameter and macroporosity percentage on bone ingrowth. *Biomaterials* 1998 Jan Feb;19(1-3):133-9.
07. Martinetti R, Belpassi A, Nataloni A, Biasini V, Martignani G: Idrossiapatite porosa sintetica per sostituzioni ossee: Caratterizzazione Chimico-Fisica. *Biomateriali: Atti del Congresso*; 51 55, Roma Enea, 1999
08. Martinetti R, Belpassi A et al.: Key Engineering Materials Vols. 192-195 (2001), 507-510 – Proceeding of the 13th Int. Symp. On Ceramics in Medicine, Bologna, Italy, 22-26 Nov.
09. Caplan AI: Mesenchymal stem cells. *J Orthop Res* 9: 641-650, 199
10. Nyman S, Lindhe J, Karring T et Rylander H: New attachment following surgical treatment of human periodontal disease. *Journal of Clinical Periodontology* 9: 290-296, 1982; 39
11. Hämmerle CH, Brägger U, Bürgin W, Lang NP: The effect of subcrestal placement of the polished surface of ITI implants on marginal soft and hard tissues. *Clin Oral Implants Res.* 1996 Jun;7(2):111-9
12. Chin M: Distraction Osteogenesis in Maxillofacial Surgery. In Lynch SE, Genco RJ, Marx RE (eds). *Tissue Engineering – Application in Maxillofacial Surgery and Periodontics*. Illinois; Quintessence Publishing Co, Inc, 1999; 147
13. Arun K. Garg: Grafting Materials in Repair and Restoration. In Lynch SE, Genco RJ, Marx RE, (eds). *Tissue Engineering - Application in Maxillofacial Surgery and Periodontics*. Illinois; Quintessence Publishing Co, Inc, 1999; 83
14. Scipioni A, Bruschi GB, Calesini G: The edentulous ridge expansion technique: A five-year study. *Int J Periodont Rest Dent* 14: 451-459, 1994 Trans Tech Publications, Switzerland
15. Schenk RK and Buser D: Osseointegration: a reality. *Periodontology* 2000, Vol 17. 1998, 22.35
16. Bauer TW and Muschler GF: Bone graft materials. An overview of the basic science. *Clin Orthop Relat Res*, 2000 Feb;(371):10-27.



Alloplastic Grafts - Beta-tricalcium phosphate

Presentation of clinical cases

Mario Ernesto García-Briseño

DDS and Professor in Periodontics - Autonomous University of Guadalajara (UAG), Mexico

This case report presents a brief review of bone loss due to periodontal infection and tooth extraction, and evaluates the biological characteristics, description and indications of an alloplastic graft material, beta-tricalcium phosphate, as an alternative treatment in two clinical cases.

Introduction

The effects of periodontal infection and its consequences, attachment and bone losses, result in the formation of periodontal bone defects (1,2). Tooth extraction involves two processes, the healing of the alveolus (3) and any change that may appear during post-extraction healing (4). The clinical consequences of tooth extraction are the resorption of the alveolar ridge (5) and the pneumatization of the maxillary sinus (6). If the effects of periodontal disease and tooth extraction are combined, the consequences will be even more severe and will complicate tooth restoration (7). The use of bone grafting materials prevents and/or repairs the insufficient bone conditions due to the previously mentioned situations (8). We will first evaluate the biological characteristics (9) of the

alloplastic graft material, beta-tricalcium phosphate, before presenting Clinical Cases using a commercial presentation of beta-tricalcium phosphate. The objective of this presentation is to demonstrate the clinical applications of beta-tricalcium phosphate alloplastic graft in periodontal bone defects and extraction sites.

Modifications in the Alveolar Process

The most common modifications involving the bone tissue of the oral cavity are: Horizontal bone loss due to periodontal infection, bone defects caused by periodontal disease, tooth extraction resulting in vertical and horizontal

resorption, pneumatization of the maxillary sinus and a combination of these. The clinical consequence of these conditions are inappropriate bone dimensions for prosthetics on natural abutment teeth and the placement of its substitutes, dental implants (10).

Periodontal bone defects

As a result of inflammatory and immune reactions to the presence of bacterial plaque and the way in which it progresses apically over the cement surface in one of the periodontal attachment components, the alveolar bone, specific patterns of destruction can be observed. These patterns depend mainly on the type of subgingival bacterial plaque and the anatomical characteristics of the alveolar process (11). Basically there are two bone loss patterns, horizontal or vertical forms. The vertical form of bone loss has been described as intrabony loss and the resulting defects have been historically classified according to the number of bone walls lost: one, two or three-wall intrabony defects. Other bone loss patterns have been described as osseous craters and circumferential defects. The special anatomy of molars and premolars involves furcations as a special condition in periodontal defect (12).

Tooth extraction

The consequences of tooth extraction represent specific conditions and a special challenge in conventional restorative dentistry and oral rehabilitation, especially with the use of dental implants (13). Whether in case of single or multiple implants - as abutments for fixed bridges and/or removable prosthesis - or in complete oral rehabilitation, the bone loss that follows tooth extraction in alveolar area or in edentulous arch represents a clinical challenge (14). The consequences of this biological process are both functional -which complicates the prosthesis design - and aesthetic, especially in the anterior zone. After tooth extraction, the

alveolus has a very high and predictable chance of healing in a natural and healthy way without any intervention. The biological principle of the alveolus repair is based on the formation of a blood clot that covers it completely. Post-extraction healing process has been accurately described. The stages of this natural process may be summarised in the following manner: At 30 minutes: clot; at 24 hours: formation of blood clot and haemolysis; at 2-3 days: formation of granulation tissue. At 4 days: increase in fibroblast density and epithelial proliferation over the edge of the wound and presence of osteoclasts indicating the alveolus remodelling. At 1 week: defined vascular network and maturing connective tissue; osteoid formation in the bottom of the alveolus. At 3 weeks: dense connective tissue; full epithelial cover. At 2 months: full bone formation is complete but without reaching the original height (15,16).

Graft Material Characteristics

Autogenous bone is the only graft material that meets the requirement of being osteogenic activating new bone formation via viable osteogenic cells (Periosteum osteoblasts, endosteum, bone marrow cells, perivascular cells and undifferentiated and/or stem cells) which are transplanted with the material and is considered as the "Gold Standard" as it also has osteoinductive and osteoconductive properties (17,18). The term "Osteoinduction" implies the biological effect of inducing differentiation of pluripotent undifferentiated cells and/or potentially inducible cells to express the osteoblast phenotype leading to new bone growth both within bone tissue and in ectopic sites. i.e. sites in which there is no natural bone formation. Even though there are several molecules able of inducing "de novo" bone tissue formation, the Bone Morphogenetic Protein (BMP) is the main protein involved (19). The term "Osteoconduction" refers to the characteristic of the graft material to act as a scaffold or mesh on which existing bone cells can proliferate and form new bone. In the absence of this supporting structure

provided by the material, the defect or bone surface would be filled or covered by fibrous soft tissue. The porosity, pore size, shape, particle size and physical/chemical characteristics influence the biological effects of cell adhesion, migration, differentiation and vascularisation at the receptor site (20,21).

Classification of graft materials by origin

Autogenous materials or Autografts are tissues from the same individual transplanted from one site to another. Viable cortical or spongy/medullar bone is commonly used in periodontology and maxillofacial surgery. Allogenic materials or Allografts are tissue from one individual of the same species; usually via a freeze-drying process; bone and skin are the most common ones. Xenografts are tissue from different species; mainly mineral bone component or collagen. Alloplastic graft materials are synthetic materials, i.e. they are manufactured by industrial processes and the most representative in medical dental use are Hydroxyapatite, β -Tricalcium Phosphate and Bioactive glasses or polymers (22).

Beta-tricalcium phosphate

Beta-tricalcium phosphate (β -TCP) is a synthetic ceramic bone graft material which has been used in orthopaedic and dentistry -periodontology and maxillo-facial surgery -for more than 30 years (23). β -TCP can be treated during the manufacturing process so that it has a structure similar to the bone mineral component, either in a block or in particles similar to spongy or trabecular bone (24). This structure has randomly interconnected pores. Porosity may range from 20% to 90%. The variation in pore size ranges from $5\mu\text{m}$ to $500\mu\text{m}$ depending on the particle size. The particle size in dental use is generally inferior to $1000\mu\text{m}$. The mechanism of action of β -TCP as a graft material is via

osteoconduction with the subsequent resorption and replacement by host bone. (25) Osteoconduction is facilitated by the interconnection between pores. In the biological process the material is resorbed and replaced by bone from the receptor individual. When the graft is placed in the receptor site, serum proteins are adsorbed on the surface of the particles, which later favours cell migration to initiate neo-vascularisation in the porous structure. Over time, the particles inferior to 1 micron start to dissolve and are then resorbed in a process mediated by phagocytic cells, thus allowing bone deposit over the material. The level of porosity and the particle size will define the resorption rate and the bone replacement process which occurs in 9 to 12 months in average (26).

Case Report no.1

48-years-old male patient in general good health conditions with two localized areas presenting some discomfort since a couple of months mainly in tooth 15 where the patient refers recurrent swelling but without need to take analgesics. A full periodontal examination reveals a localized distal periodontal probing of 10 mm. with bleeding and suppuration and a mild redness (*Fig. 1*).

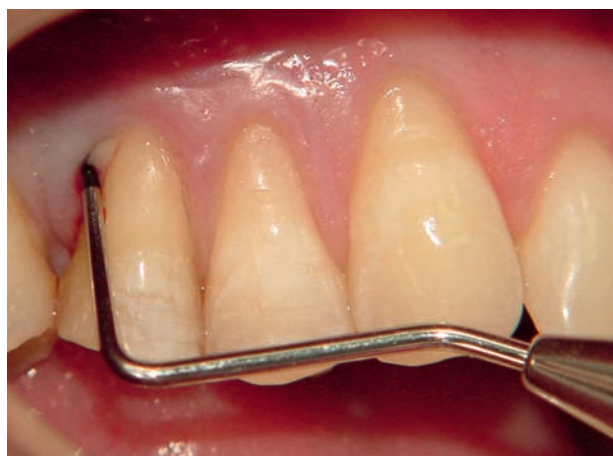

Fig. 1: Bleeding and suppuration in 10 mm pocket in tooth 15

On X-ray examination a wide distal intrabony-two walls defect is present (*Fig. 2*). The previous root canal treatment seems without complications in the periapical area. The localized periodontal attachment loss and the overall periodontal health could support the etiology of pulpar complication i.e. a lateral canal since the patient report at least 8 years of root canal treatment after a painful episode in the tooth.

A flap debridement procedure is indicated and it is confirmed the bone defect and irregular bone loss in the vestibular cortical plate. (*Fig. 3*).

With the pulpar involvement as main etiology an effort is done to find clinical evidence i.e. localized area of resorption and/or lateral foramen without confirmation. It is decided to use β -tricalcium phosphate "R.T.R." (Septodont) as a graft material. (*Fig. 4*).

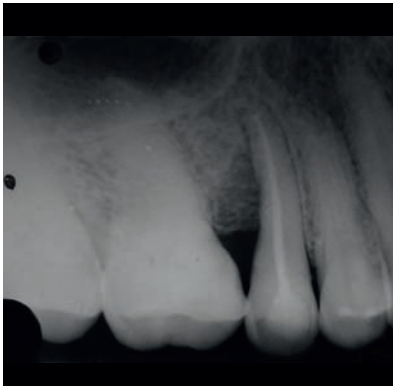


Fig. 2: Initial X-ray showing the intrabony-two walls defect.

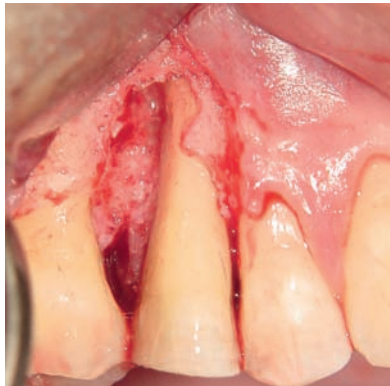

Fig. 3: After debridement, scaling and root planning a complicated bone loss is present.

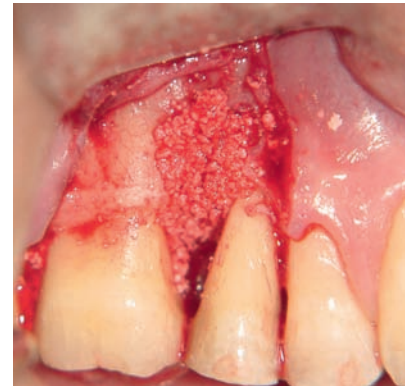

Fig. 4: β -tricalcium phosphate "R.T.R." (Septodont) as a graft material.

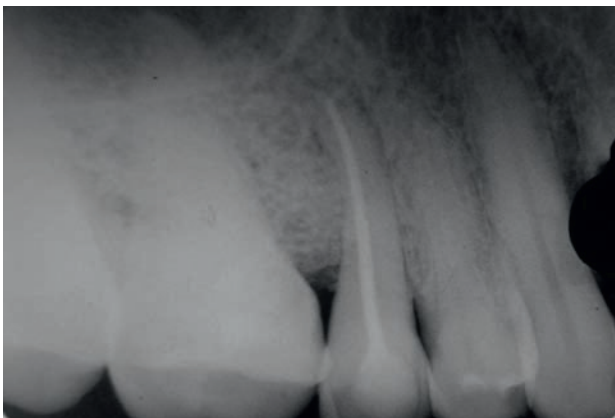


Fig. 5: X-ray taken immediately after the surgical procedure showing the particles of β -tricalcium phosphate "R.T.R." (Septodont) in the defect.

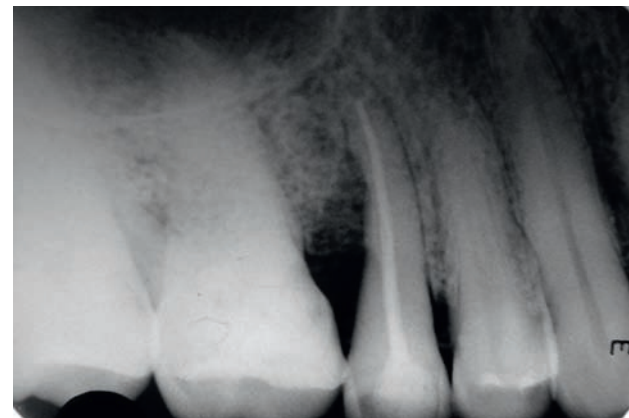

Fig. 6: X-ray six months post-surgery where the particules of β -tricalcium phosphate "R.T.R." (Septodont) has been replaced with recently formed trabecular bone and the bone defect appears with some lateral reduction.

Case Report no.2

A second problem is identified at the periodontal examination in tooth 46 and confirmed with the X-ray. An extensive root resorption on the distal root is present (*Fig. 7*) with any symptom reported by the patient except some discomfort and "bad taste" occasionally. The root canal treatment was done at the same time than tooth 15 (eight years before). The clinical condition makes difficult to try endodontic retreatment or other treatment options like hemisection, the extraction

is indicated. In order to avoid the collapse of the residual alveolar bone and the socket, particles of β -tricalcium phosphate "R.T.R." (Septodont) is used as graft material. (*Fig. 8,9*).

Conclusion

In concepts of Osteogenesis, remains today still open the debate as to which type of currently available bone grafting material is the best.

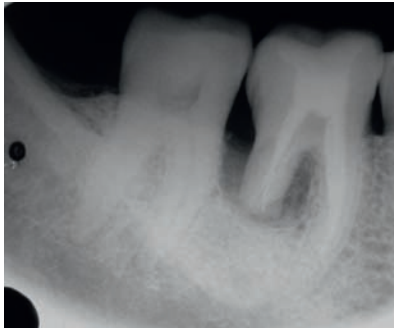


Fig. 7: X-ray showing extensive root resorption on the distal root of tooth 46.

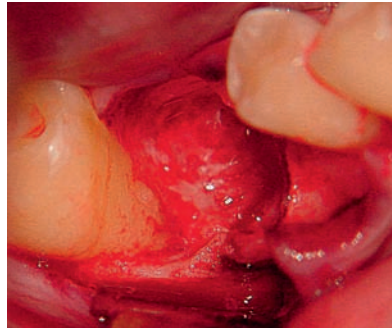


Fig. 8: Clinical view showing the extensive bone loss in the residual ridge after the tooth extraction. Notice the minimal width at the crestal area in the buccal and lingual plates and the attachment loss at the mesial root of tooth 47.

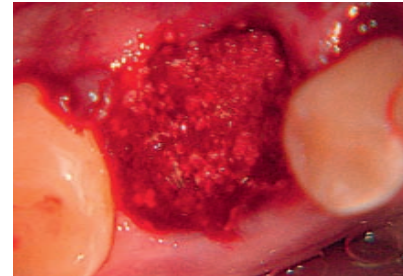


Fig. 9: Composite blood clot and β -tricalcium phosphate "R.T.R." (Septodont) used as graft material prior the suture. In the area of resorption a cone shaped β -tricalcium phosphate "R.T.R." (Septodont) is used and in the mesial root alveolus particles of β -tricalcium phosphate "R.T.R." (Septodont) are used.

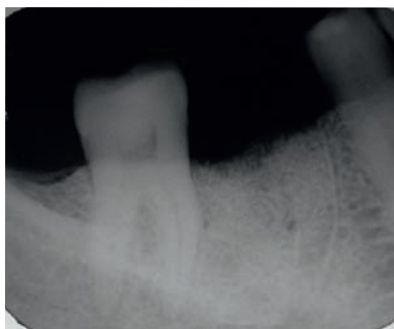


Fig. 10: X-ray taken immediately after the surgical procedure showing β -tricalcium phosphate "R.T.R." (Septodont) in the bone defect and mesial root alveoli

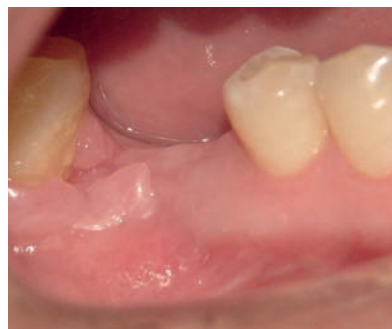

Fig. 11: 6 months of clinical healing.

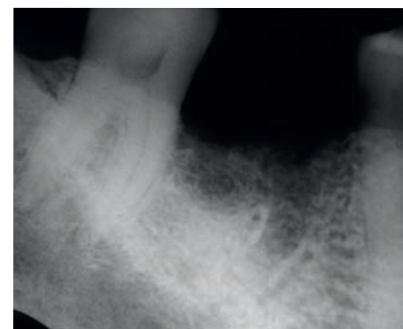


Fig. 12: X-ray 6 months post-surgery where the particles of β -tricalcium phosphate "R.T.R." (Septodont) have been replaced by recently formed trabecular bone in the bone defect and mesial root alveolar.



Author: Dr Mario Ernesto García-Briseño

DDS at Universidad Autónoma de Guadalajara, México, 1976.

Certificate program in Periodontology at Universidad Nacional Autónoma de México 1985-87.

Director and Professor of the certificate program in Periodontology since 1992 to date at Universidad Autónoma de Guadalajara School of Dentistry.

Professor of Periodontology at certificate programs in Endodontics,

Orthodontics, and Oral Rehabilitation since 1992 at Universidad Autónoma de

Guadalajara School of Dentistry.

Founder and President of the Mexican Association of Periodontology 1996-98.

Founding member and Secretary of the Mexican Board of Periodontology 1996/2001.

Academy affairs coordinator College of Dental Surgeons of Jalisco 2000/2004.

Founder and academic coordinator of the College of Periodontics GDL.

National and international lecturer.

Private practice in Periodontics and Implant Dentistry.

References

01. Listgarten MA. Pathogenesis of periodontitis. *J Clin Periodontol*. 1986; 13: 418-425.
02. Waerhaug J. The angular bone defect and its relationship to trauma from occlusion and down growth of subgingival plaque. *J Clin Periodontol* 1979; 6: 61-82.
03. Boyne PJ. Osseous repair of the postextraction alveolus in man. *Oral Surg Oral Med Oral Pathol* 1966; 21:805-813.
04. Pietrokovski J, Massler M. Alveolar ridge resorption following tooth extraction. *J Prosthet Dent* 1967;17:21-27.
05. Seibert JS. Reconstruction of deformed, partially edentulous ridges, using full thickness onlay grafts. Part I. Technique and wound healing. *Compend Contin Educ Dent* 1983;4:437-453.
06. Smiler DG, Johnson PW, Lozada JL, et al. Sinus lift grafts and endosseous implants. Treatment of the atrophic posterior maxilla. *Dent Clin North Am* 1992;36:151-186.
07. Lekovic V, Kenney EB, Weinlaender M, et al. A bone regenerative approach to alveolar ridge maintenance following tooth extraction. Report of 10 cases. *J Periodontol* 1997;68:563-570.
08. Mellonig, JT. Autogenous and Allogeneic Bone Grafts in Periodontal Therapy. *Crit Rev Oral Biol* 19923(4):333-352
09. Jarcho M. Biomaterials aspects of calcium phosphates. Properties and applications. *Dent Clin North Am* 1986;30:25-47.
10. Dhingra K. Oral Rehabilitation Considerations for Partially Edentulous Periodontal Patients *J Prosthodontics* 21 (2012) 494-513
11. Listgarten MA. Pathogenesis of periodontitis. *J Clin Periodontol*. 1986; 13: 418-425.
12. Waerhaug J. The angular bone defect and its relationship to trauma from occlusion and down growth of subgingival plaque. *J Clin Periodontol* 1979; 6: 61-82.
13. Zitzmann NU, Krastl G, Walter C, et al: Strategic considerations in treatment planning: deciding when to treat, extract, or replace a questionable tooth. *J Prosthet Dent* 2010;104:80-91
14. Craddock HL, YoungsonCC, Manogue M, Blance A. Occlusal Changes Following Posterior Tooth Loss in Adults. Part 2. Clinical Parameters Associated with Movement of Teeth Adjacent to the Site of Posterior Tooth Loss *J Prosthodont* 2007;16:485-494.
15. Amler MH. The time sequence of tissue regeneration in human extraction wounds. *Oral Surg* . 1969 27; 309-318
16. Boyne PJ. Osseous repair of the postextraction alveolus in man. *Oral Surg Oral Med Oral Pathol* 1966; 21:805-813.

References

17. American Academy of Periodontology. Glossary of Periodontol Terms, 4th ed. Chicago: American Academy of Periodontolgy; 2001;44.
18. Reynold MA, Aichelmann-Reidy ME, Branch-Mays GL. Regeneration of periodontal tissue: Bone replacement grafts. Dent Clin North Am 2010;54:55-71
19. Urist MR. Bone: Formation by autoinduction. Science 1965;150:893-899.
20. Jarcho M. Biomaterials aspects of calcium phosphates. Properties and applications. Dent Clin North Am 1986;30:25-47
21. Hollinger JO, Brekke J, Gruskin E, Lee D. Role of bone substitutes. Clin Orthop 1996;Mar(324):55-65
22. Gross JS. Bone grafting materials for dental applications: a practical guide. Compend Contin Educ Dent. 1997;18:1013-1036
23. Labanca M, Leonida A, Rodella FL Natural or synthetic biomaterials in Dentistry: Science and ethic as criteria for their use. Implantologia 2008; 1:9-23
24. Metsger D.S. et al. (1982). Tricalcium phosphate ceramic--a resorbable bone implant: review and current status. J Am Dent Assoc.105: 1035-1038.
25. Jensen SS, Brogini N, Hjorting-Hansen E, Schenk R, Buser D. Bone healing and graft resorption of autograft, anorganic bovine bone and beta-tricalcium phosphate. A histologic and histomorphometric study in the mandibles of minipigs. Clin Oral Implants Res 2006; 17:237-243.
26. Artzi Z, Weinreb M, Givol N, et al. Biomaterial resorption rate and healing site morphology of inorganic bovine bone and beta-tricalcium phosphate in the canine: A 24-month longitudinal histologic study and morphometric analysis. Int J Oral Maxillofac Implants 2004;19:357-368.

Download the complete series

Septodont

Case Studies

Collection

www.septodont.com





Biodentine™

Pulpotomy on vital carious primary molars

Prof. Dr Luc Martens
Sivaprakash Rajasekharan, dental surgeon
Dr Rita Cauwels
Department of Pedodontics - UZGent

In pediatric dental care, we try to keep primary teeth free of caries until they are replaced naturally. However, extensive caries in contact with the pulp still occurs. In such cases, a timely endodontic procedure can enable us to avoid early extraction of primary teeth, thereby preserving the primary objective of dental caries treatment, which is to maintain the function of chewing, speaking, swallowing and esthetic appearance.

Introduction

Diagnosis in children presenting with pain is not always easy. Pulpal diagnosis in primary teeth is imprecise as clinical symptoms do not reflect the histologic condition of the pulp. Age and behavior may jeopardize the reliability of pain

as an indicator of the degree of pulpal inflammation. Also, asymptomatic chronic pulpitis is seen in primary molars. Therefore, adequate radiographic diagnosis is necessary in cases of multiple caries.

Why pulpotomy?

In primary teeth, pulpotomy is the most widely accepted pulpal treatment throughout the world. Above all, it is the complex root canal anatomy of the primary teeth, the proximity of permanent teeth and the absence of filling materials compatible with physiologic root resorption that determine this choice. A pulpotomy is based on the hypothesis that the inflammation and reduced vascularization, caused

by bacterial invasion, are confined to the coronal pulp, while the root pulp remains vital (*Fig. 1*)¹.

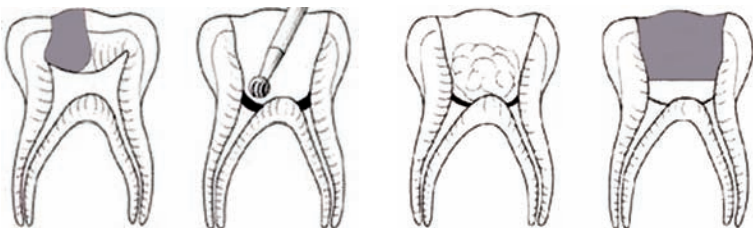


Fig. 1: Pulpotomy: Overview of preparation, control of bleeding and product application

An ideal material for pulpotomy

An ideal pulpotomy material should be bactericidal, promote root pulp healing, provide a relatively stable environment for the dentin-pulp complex, stimulate dentin-pulp complex regeneration and not disturb the physiologic process of root resorption².

What the literature tells us

Despite its limited bactericidal action and potential toxicity, formocresol is regarded as the reference standard worldwide. Iodoform pastes which have a greater bactericidal action and are histologically better tolerated are less widespread and are used more on a regional level. At the same time, scientific evidence has emerged showing that pulpotomy performed with Mineral Trioxide Aggregate (MTA) produces better clinical and radiographic results than formocresol^{3,4}. (Fig. 2).

Meanwhile, Biodentine™, a non-metallic, inorganic, tricalcium-silicate (Ca₃SiO₅)-based restorative cement, marketed and recommended as a “bioactive dentin substitute”, has been shown

to have much better physical and biologic properties, such as material handling, faster setting time, better resistance to pressure, greater leak resistance and faster dentin bridge formation compared with MTA. Although clinical studies (long-term studies) are still rare, Biodentine™ appears to be an effective substitute for MTA in pulpotomy.

How to perform pulpotomy with Biodentine™

- Remove any caries and the pulp from the pulp chamber
- Control bleeding at the canal entrances
- Mix the material following the manufacturer's instructions
- The material can be applied deep within the cavity with a spatula or amalgam carrier.

The material can be compacted using dry pluggers or cotton pellets.

On no account should the cotton pellets be moistened with water (!); any residual liquid from Biodentine™ (calcium chloride) may be used for moistening later, after which the cotton pellet should be squeezed out thoroughly using a towel.

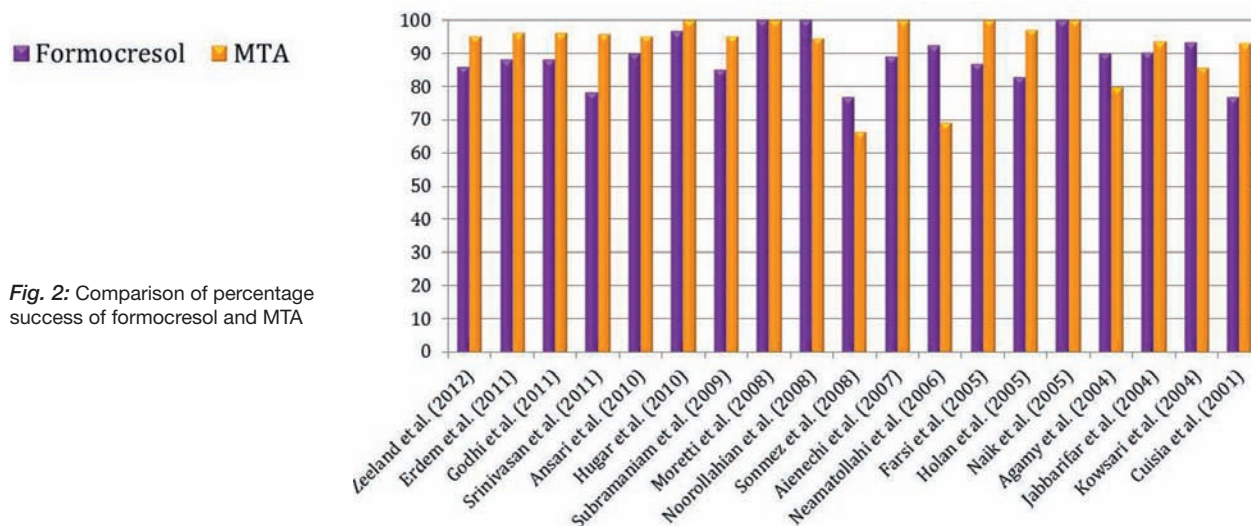


Fig. 2: Comparison of percentage success of formocresol and MTA

Choice of filling material after pulpotomy

Biodentine™ can be used as a temporary filling material that can be exposed to saliva for 6 months. This can be an advantage for lengthy treatments or in uncooperative children. If the dentist wishes to make a permanent filling, he or she is then advised to wait 6 minutes until the material has completely hardened, after which bonding restoration can be performed. Studies have shown that etching the Biodentine™ surface

with a H₃PO₄ gel for 15 seconds and applying a bonding layer achieves greater adhesive strength and less micro-infiltration⁵. It is also possible to opt for a steel crown.

Case studies

All the cases described below took place under general anesthesia as part of a randomized clinical trial (RCT).

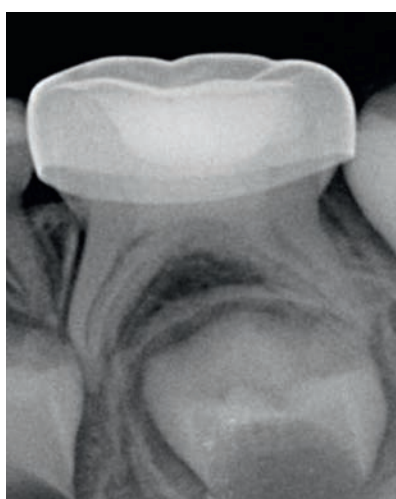

Fig. 3: Tooth 75: Radiograph after pulpotomy with Biodentine™

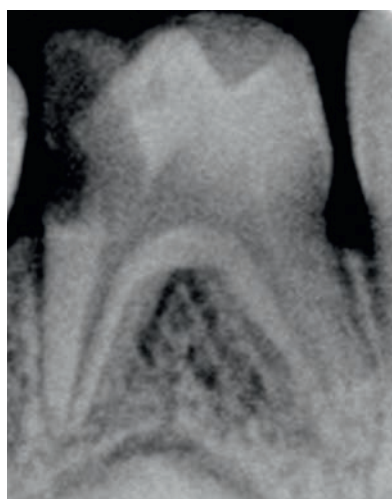

Fig. 4: Tooth 84: Radiographic diagnosis before pulpotomy

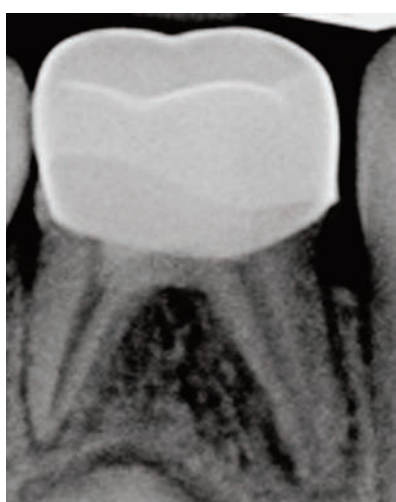

Fig. 5: Tooth 84: Radiograph immediately after pulpotomy

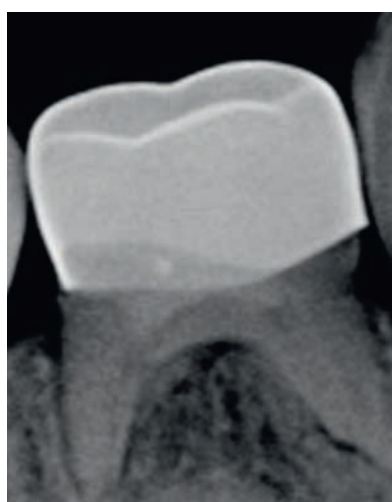

Fig. 6: Radiograph 1 year after pulpotomy

Case no.1

In a 6-year-old girl, pulpotomy with Biodentine™ was performed on tooth 75. The radiograph at one-year follow-up showed no complications whatsoever (*Fig. 3*).

Case no.2

In a 5-year-old boy in whom tooth 84 had been treated by pulpotomy with Biodentine™, the radiograph at 1-year follow-up shows complete obliteration (*Figs. 4-5-6*).

In the RCT in progress at the Pedodontics Department, obliteration is the most common observation when Biodentine™ is used for pulpotomy of primary molars. It is considered a positive sign as obliterated canal pulp usually does not cause any clinical complications.

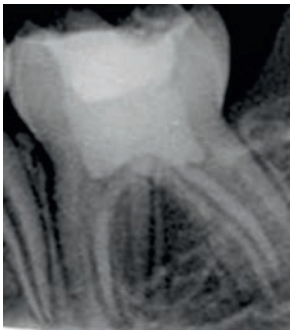


Fig. 7: Radiograph immediately after pulpotomy

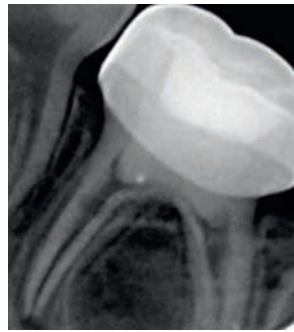


Fig. 8: Radiograph 6 months after pulpotomy: internal resorption in the mesial root

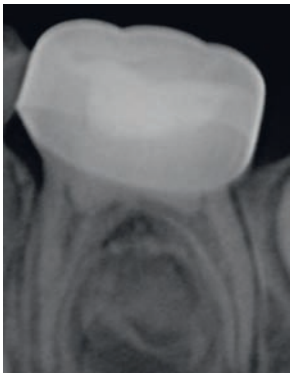


Fig. 9: 1 year after pulpotomy: process of healing via obliteration of the mesial root

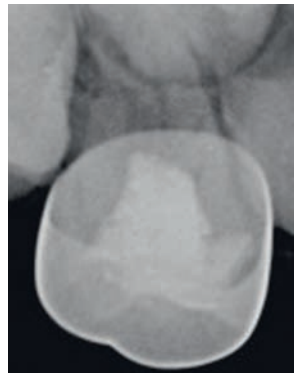

Fig. 10: Tooth 55: Radiograph after pulpotomy with Tempophore™

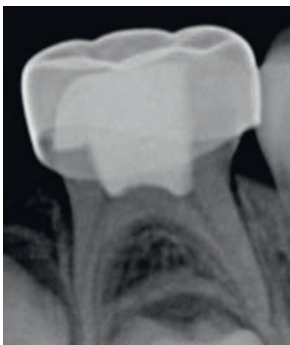

Fig. 11: Tooth 75: Radiograph after pulpotomy with MTA

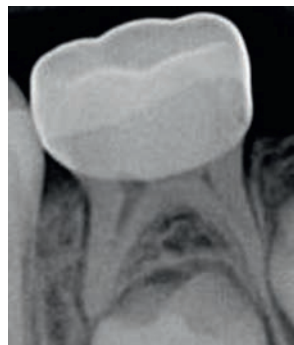

Fig. 12: Tooth 85: Radiograph after pulpotomy with Biodentine™

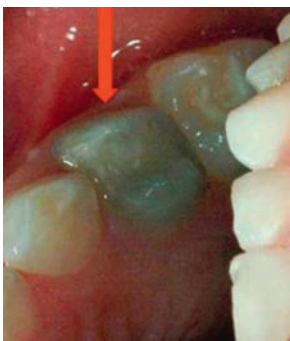

Fig. 13: Pulpotomy with MTA: Clinical follow-up at 1 year

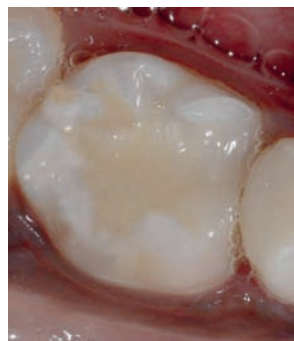


Fig. 14: Pulpotomy with Biodentine™: Clinical follow-up at 1 year

Case no.3

A 3-year-old girl had been treated 1 year previously for multiple caries. Pulpotomy was then performed with Biodentine™ on tooth 75 (*Fig. 7*). After 6 months of follow-up, there were no complaints such as spontaneous pain, tenderness on percussion, tenderness on palpation, increased mobility or swelling. A sign of internal resorption on the mesial root was visible on the radiograph (*Fig. 8*). It was decided to follow up the tooth every 3 months.

After 9 months of follow-up, the patient had no pain and the tooth was in order clinically.

After 12 months of follow-up, the tooth was still not causing any problems. Early obliteration was visible on the radiograph in the place of the internal resorption (*Fig. 9*). The appearance of internal resorption after pulp treatment is attributed to inflammation of the residual pulp whereas obliteration results from increased activity of odontoblast-like cells. The formation of tertiary dentin leads to obliteration and should be considered an attempt by vital pulp tissue to heal. Consequently, in the case presented above, the incipient inflammation may have been halted, leading to a healing process.

Remarks

- Owing to limited radio-opacity, it can sometimes be difficult to see dentin bridge formation and it can be confused with natural dentin. In a 6-year-old girl, 3 pulpotoomies were performed with three different materials. The radio-opacity of the 3 materials can be compared on the radiographs (*Figs. 10, 11 and 12*).

- A major advantage of Biodentine™ over MTA is the absence of grayish-black discoloration. Figure 13 shows a clinical view of a primary tooth treated by MTA pulpotomy a year earlier. Figure 14 shows a clinical view of a primary tooth treated with Biodentine™, also at 1-year follow-up. There is absolutely no discoloration.

Clinical Success

As a pulpotomy material, MTA has been shown to produce better clinical and radiographic results than formocresol. In the authors' clinical study,

no clinical or radiographic differences were found between Biodentine™ and MTA when used as a pulpotomy agent in carious primary molars.

Conclusion

The era of formocresol and other mummification products for the treatment of deep caries of vital primary molars appears to be past. In regard to MTA, a modified Portland cement, there is already a fair amount of evidence in

the literature. Biodentine™, with its superior properties in comparison with MTA, also appears to show this in clinical practice. Moreover, the absence of coronal discoloration is a major additional benefit.




Prof. Dr. Luc Martens (UGhent 1980) is full time Professor in the dental medicine education and research department of the University of Ghent and Head of the Pediatric and Special Dentistry department. He is the author and co-author of more than 100 international publications and supervised 7 doctoral theses. He implemented and developed, in collaboration with Dr Rita Cauwels, the clinical use of Biodentine™ and both in vitro and in vivo research. He lectured on these topics in Moscow (Russia), Hong-Kong (China) and Perth (Australia). He recently presented a poster in Sopot (Poland).



Dr Rita Cauwels (UGhent 1980) is currently full time practitioner in the Pediatric and Special Dentistry department at the Ghent University Hospital as a Chief resident. She is dedicated to 2nd and 3d line care with a special expertise in traumatology and laser-therapy. She obtained her thesis on "Treatment improvement of traumatized immature teeth" in 2012 at the Ghent University. She initiated, with Prof. Martens, the clinical development of Biodentine™. She lectured on this topic in Strasbourg (France) and Ljubljana (Slovenia) and recently presented a poster in Sopot (Poland).

References

01. Guidelines. American Academy of Pediatric Dentistry. Pediatric dentistry. 1996;18(6):30-81. Epub 1996/11/01.
02. Zhang W, Yelick PC. Vital pulp therapy-current progress of dental pulp regeneration and revascularization. International journal of dentistry. 2010;2010:856087. Epub 2010/05/11.
03. Simancas-Pallares MA, Diaz-Caballero AJ, Luna-Ricardo LM. Mineral trioxide aggregate in primary teeth pulpotomy. A systematic literature review. Medicina oral, patologia oral y cirugia bucal. 2010;15(6):e942-6. Epub 2010/06/08.
04. Peng L, Ye L, Tan H, Zhou X. Evaluation of the formocresol versus mineral trioxide aggregate primary molar pulpotomy: a meta-analysis. Oral surgery, oral medicine, oral pathology, oral radiology, and endodontics. 2006;102(6):e40-4. Epub 2006/12/02.
05. Boinon C, Bottero-Cornillac MJ, Koubi G, Déjou J. Evaluation of adhesion between composite resins and an experimental mineral restorative material. European Cells and Materials. 2007;13(Suppl. 1).



Biodentine™ Pulp capping

Prof. Dr Luc Martens
Dr Rita Cauwels
Department of Pedodontics - UZGent

Often, after removal of caries, the pulp becomes transparent or is exposed. Hence dentists are often faced with the dilemma of starting endodontic treatment or delaying it in favor of pulp capping. This involves placing a “medicine” on the exposed pulp or over the ultrafine dentin layer with the specific aim of preserving pulp vitality. Calcium hydroxide has been used as the reference standard for this for several decades. Meanwhile, Mineral Trioxide Aggregate (MTA) has become a popular alternative.

Although a Cochrane review reports that the evidence is still insufficient, the recent literature shows, over a 2-year period, that the success rate for MTA, like that of original Portland cement, can be as much as 100%. In this article, we compare MTA and calcium hydroxide and discuss and illustrate the use of Biodentine™ as a capping material in the treatment of deep caries in children’s permanent molars.

Introduction

It is a well-known fact that calcium hydroxide has a major antibacterial action and thereby minimizes or eliminates bacterial penetration. While this has been recognized for decades, the healing mechanism has only recently been described. “Bone morphogenetic protein” and “bone transforming growth factor beta 1” play a very important role here, in both pulp healing and new dentin formation.

However, the disadvantages of calcium hydroxide are that it does not have good adhesion on its own, resulting in poor sealing, and that it is highly soluble.

MTA, well known as an aggregate of tricalcium silicate, dicalcium silicate and tricalcium alumi-

nate, has, with water, calcium hydroxide as its principal reaction product. It is to this that MTA owes its biocompatibility. Moreover, a single seal with dental tissue

is found, following a bioactive reaction. Another disadvantage is its high solubility and long setting time.

Three studies were published between 2003 and 2008 in which no clinical differences were found between calcium hydroxide and MTA, while 4 other studies considered MTA to be more effective. However, histologic studies revealed that there was less pulpal inflammation with MTA and that a tissue barrier with superior hardness was formed. A very recent (2013)

practice-based randomized clinical trial has established the superiority of MTA as a direct capping material.

As regards Biodentine™, various in vitro animal experiments have established its biocompatibility, bioactivity and ability to induce pulp healing. In a study on direct capping in piglets, Biodentine™ showed much faster hard tissue induction than calcium hydroxide in the short term (1 week). However, beyond 3 months, no further difference

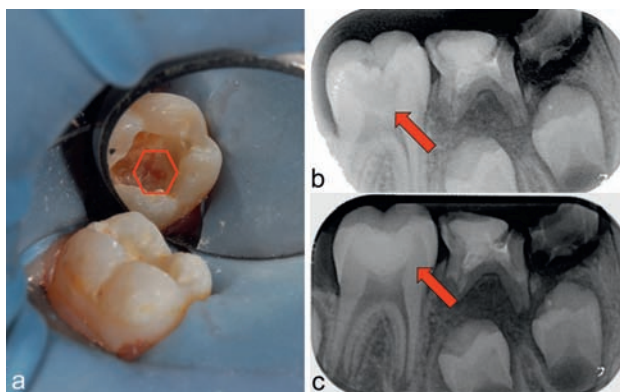


Fig. 1: Indirect capping of tooth 46 with Biodentine™

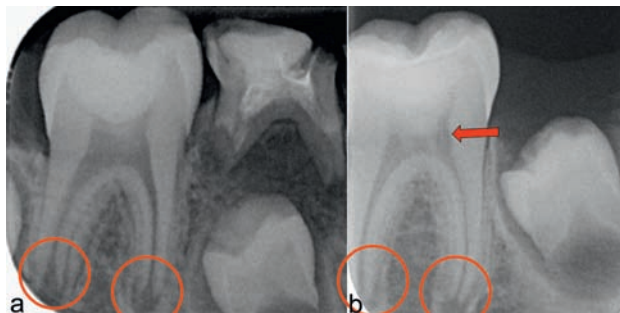

Fig. 2: Radiograph after treatment (2a) and at 12-month follow-up (2b)

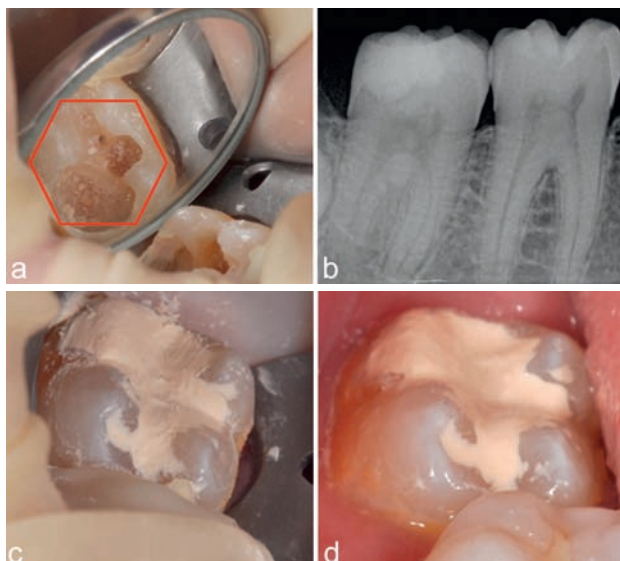


Fig. 3: Deep caries on tooth 47 (a) and radiograph after treatment with Biodentine™ (b) clinical view after immediate treatment with Biodentine™ (c) and after 4 weeks (d)

in barrier formation was observed. It was shown, via a “human dental culture model”, that Biodentine™ and ProRoot™ MTA both initiated reparatory dentin synthesis. The possibility of inducing cell proliferation as well as biomineralization was clearly demonstrated on immortalized murine pulp cells.

In a study of human pulp in which capping was performed on premolars due for extraction for orthodontic reasons, no difference between MTA and Biodentine™ was apparent. In both cases, complete dentin bridges were observed in the presence of inflammatory cells. Moreover, layers of odontoblasts and pseudo-odontoblastic cells forming tubular dentin were observed. Besides the good histologic reactions established since then, Biodentine™ has the added advantage that discoloration never occurs (unlike MTA) and that the material can act as a temporary filling material and be exposed to saliva for a certain number of months. This is comforting for both patient and practitioner.

Case report

Patient A (7 years) presented for treatment of caries on tooth 46. He had not previously complained of pain. During curettage (see Fig. 1a), the pulp was almost exposed. After eccentric removal of all the caries, indirect capping was performed with Biodentine™, after which the entire cavity was filled with it. Figures 1b and 1c show the radiographic image before and after. During follow-up, no subjective complaint was reported. After only a year, the continued formation of radicular apices was apparent on radiographs. The formation of hard tissue in the pulp chamber is also probable (Fig. 2b).

In patient B (14 years) very deep caries was found on tooth 47 during treatment (Fig. 3a). There had been no previous symptoms. Biodentine™ was placed inside the entire cavity (Fig. 3b). Figures 3c and 3d illustrate Biodentine™ in place immediately after treatment and a few weeks later, respectively. Due to its special properties, Biodentine™ can be used as a temporary

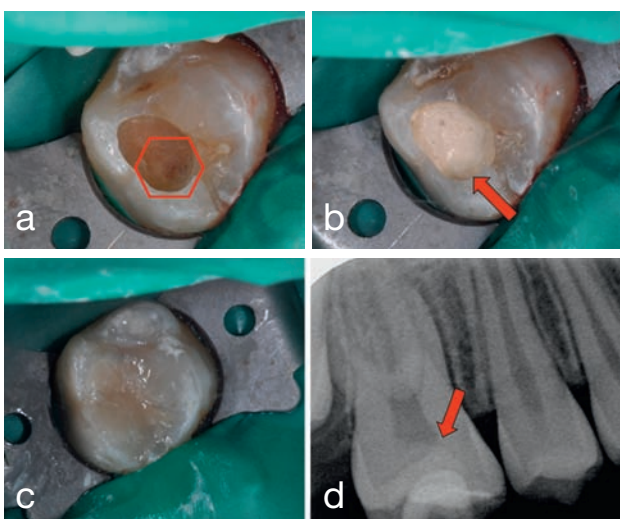


Fig. 4: Deep caries on tooth 16 (a) and clinical view after immediate treatment with Biodentine™ as a cavity liner (b). A composite restoration (c) was placed at the same visit and a control radiograph was obtained (d)

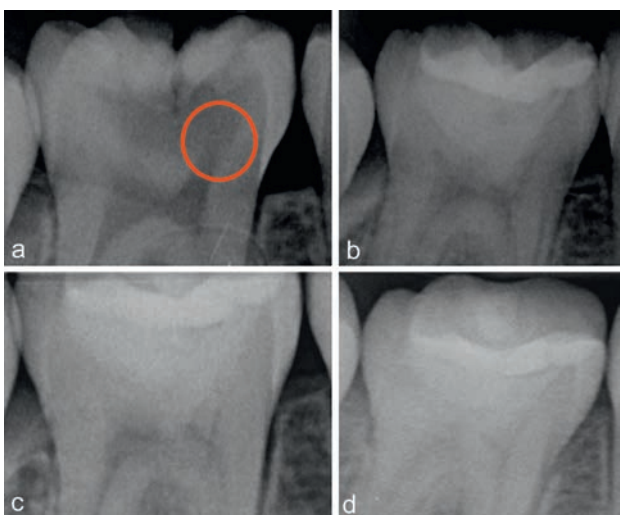

Fig. 5: Deep caries on tooth 46 (a), treatment with Biodentine™ (b) and control radiographs after 4 and 8 months (c, d). With our thanks to Bieke Kreps, dental surgeon

filling material, unlike MTA. Here also, there were no complaints of pain during the follow-up period. In patient C (12 years) who had absolutely no complaints previously, an occlusal lesion was treated and the pulp was almost exposed unexpectedly (*Fig. 4a*). Biodentine™ was placed here as a cap and cavity lining (*Fig. 4b*) and immediate restoration with composite was performed (*Fig. 4 c, d*). The patient had no complaints of pain during the follow-up period.

In patient D (11 years) deep caries on tooth 46 was detected radiographically, on which pulp exposure appeared inevitable (*Fig. 5a*). Direct capping with Biodentine™ was performed (*Fig. 5b*). There were no further complaints at follow-up. The control radiographs suggest the formation of hard tissue after 4 and 8 months (*Fig. 5 c, d*).

Conclusion

Biodentine™ calcium silicate cement is suitable for use as a capping material for deep carious lesions and pulp exposure. The material can be used as a temporary filler and can be exposed to saliva for a certain number of months and act as a cavity liner, on which an immediate composite restoration can be placed. Clinical follow-ups reveal no complaints from patients at 2-3 years. Radiographs show continued maturation of immature molars and hard tissue formation can be seen in pulp chambers.

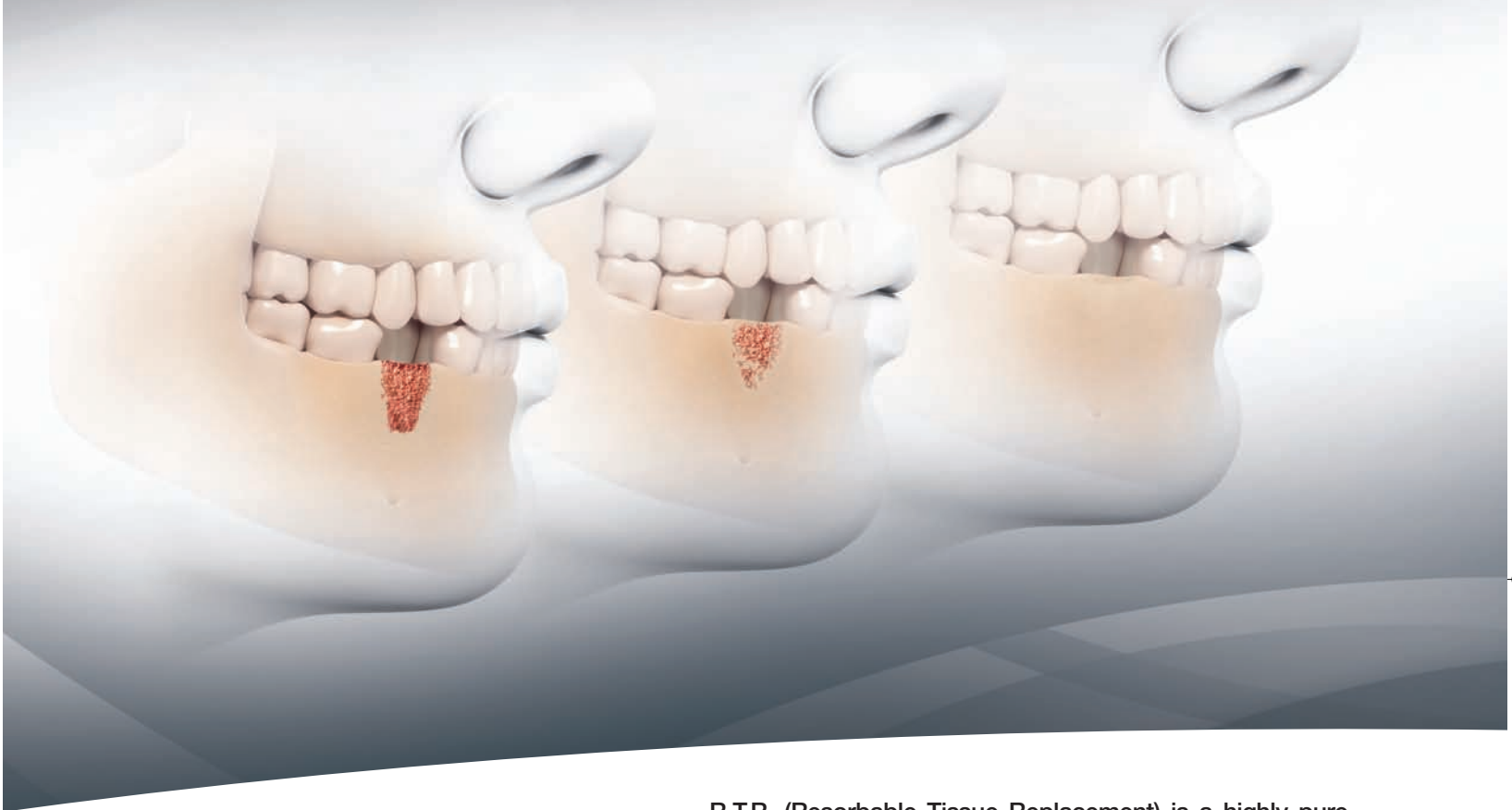
References

- Hilton TJ. Keys to clinical success with pulpcapping: a review of the literature . *Oper dent* 2009;34:615-625.
- Hilton TJ, Ferracane JL, Mancl L., Comparison of CaOH with MTA for Direct Pulp capping: A PRBN Randomized Clinical Trial. *J Dent Res* 2013;92;1:16-22.
- Nowicka A, Lipski M, Parafiniuk M et al., response of Human dental Pulp Capped with Biodentine™ and Mineral trioxide Aggregate; *JOE* 2013;39:6:743-747.
- Ng FK, Messer LB Mineral trioxide aggregate as a pulpotomy medicament: An evidence based assessment. *Eur Arch Paed Dent* 2008;9(2):58-73.
- Oliveira TM, Moretti ABS, Sakai VT et al., Clinical, radiographic and histologic analysis of the effects of pulp capping materials used in pulpotomies of primary teeth. *Eur Arch Paed Dent* 2013;14:65-71.
- Shayegan A, Jurysta, Atash, Petein, Abbeele AV. Biodentine™ used as a pulpcapping agent in primary pig teeth. *Pediatr dent* 2012;34:e202-8.
- Zanini M, Sautier JM, Berdal A, Simon S. Biodentine™ Induces Immortalized Murine Pulp Cell differentiation into Odontoblast-like cells and Stimulates Biomineralization. *JOE*2012;38:9-1220-1226.

R.T.R.

Full resorption...

...Strong new bone formation



Cone



Syringe



Granules

R.T.R. (Resorbable Tissue Replacement) is a highly pure β -tricalcium phosphate bone grafting material that helps to safely create new bone formation following an extraction or any bone loss (intrabony defect, sinus-lift...).

- **Resorbs progressively and fully:** R.T.R. releases calcium and phosphate ions helping to promote strong new bone formation.
- **Regenerates natural bone growth.** Osteoconductive micro and macroporous structures foster dense new bone growth.
- **Restores volume:** R.T.R. renews the bone integrity within 3-6 months.
- **Available in 3 presentations** (Cone, Syringe, Granules) to suit all clinical situations.

Improve your patients' extraction therapy and bone loss repair to promote future implant success with R.T.R.

R.T.R. Cone contains collagen from bovine origin





The Dental Pharmaceutical Company

INNOVATIVE, SAFE AND EFFECTIVE SOLUTIONS FOR DENTISTRY WORLDWIDE

